Assessing for Vascular Injury Following a Knee Dislocation

Michael Roberts, MA, ATC, BCS-O, OTC

Ortho Nebraska

SYMPOSIUM

Conflict of Interest

- I have no conflicts of interest related to this presentation
- I have no disclosures to make

Background

- Knee dislocations are rare injuries with potentially devastating vascular complications
- Failure to diagnose a vascular injury that occurs as a result of a knee dislocation can result in amputation
- There are wide discrepancies in the reported frequency of vascular injury following knee dislocation
- There are also differences among the approaches for diagnosis of vascular injuries following knee dislocation

In the News

Ortho Nebraska

Objectives

- Recognize the associated risk of vascular injury in patients following a knee dislocation
- Recognize the role of the ABI in assessing for vascular injury following a knee dislocation
- Explain the process of conducting an ABI
- Interpret ABI results and recognize abnormal findings
- Recognize the potential barriers in practice to performing an ABI
- Identify possible solutions to ensure prompt and timely care for athletes following a knee dislocation with possible vascular injury

Knee Dislocations and Vascular Injury

- Defined as clinical or radiological loss of tibio-femoral congruity
- Many knee dislocations spontaneously reduce, thus are associated with multi-ligament disruption
- Research indicates 18-64% of knee dislocations have an associated vascular injury
  - 80% of these cases underwent vascular repair
  - 12% underwent amputation
- Early treatment is critical!
  - Treatment of vascular injuries following dislocation within 8 hours resulted in 11% amputation rate
  - Delay beyond 8 hours results in 86% amputation rate
  - Residual amputation rates following surgery still 10%

Ortho Nebraska

(Pardiwala et al., 2017)

Knee Dislocations

- Epidemiology
  - Account for <.02% of all orthopedic injuries
    - Although not common, associated with short-term and long-term complications
      - Vascular injuries
      - Neurological deficits
      - Degenerative joint disease
  - Accounts for <.5% of all joint dislocations
  - 33% of knee dislocations are secondary to sports injuries
  - 50% due to traffic accidents
  - From 2007-2012 there were an estimated 9,369 knee dislocations in the United States
    - Incidence was most likely in 10–19-year-olds, and more likely to happen in males

- Etiology
  - High-Energy Traumas- MVA's and fall from heights
  - Low-Energy Trauma- Sporting activities

Ortho Nebraska

(Pardiwala et al., 2017)

Anatomy Review- Major Ligamentous Structures

- ACL
- PCL
- MCL
- LCL

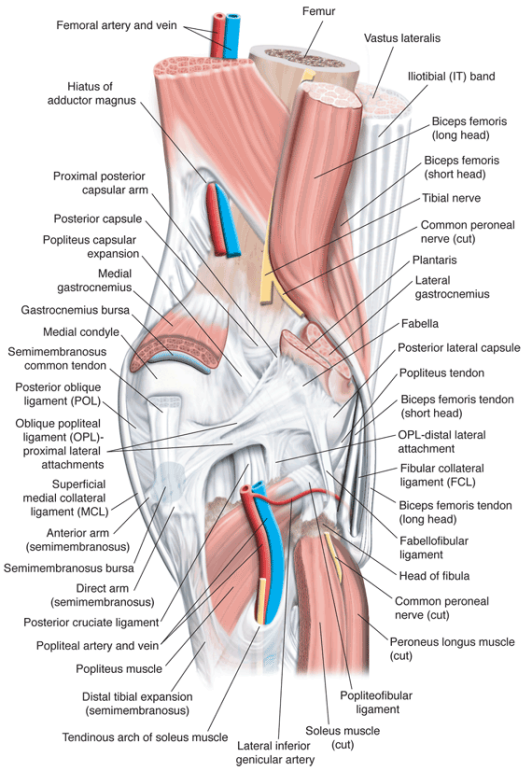

(The structures of the posterolateral corner, n.d.; Wilson, 2019)

Anatomy Review- Neurological

- Peroneal nerve

(Peroneal Nerve, 2019)

Anatomy Review- Vascular

- Most injured blood vessels
  - Popliteal artery
  - Anterior tibial artery
  - Medial genicular arteries
  - Posterior tibial artery

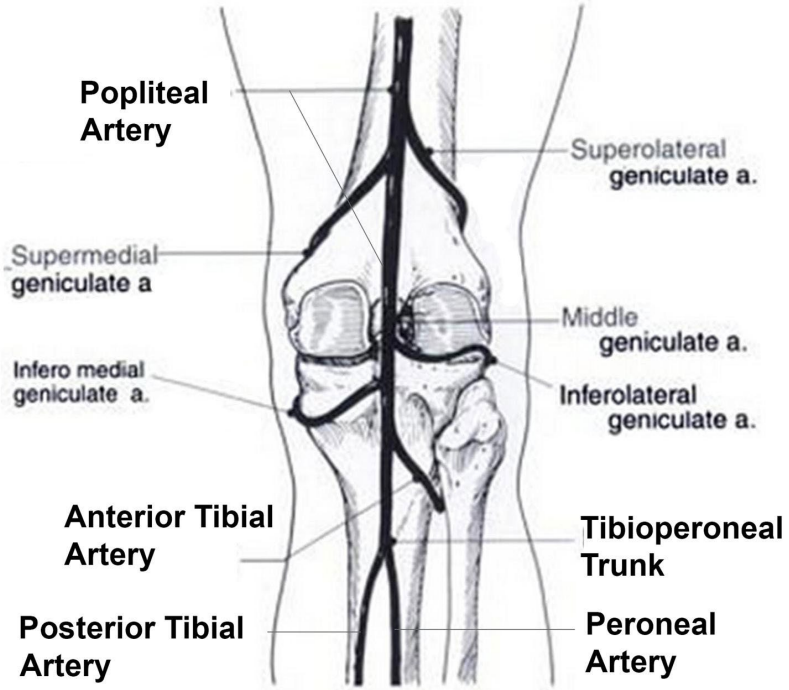

(Sheth, 2016)

Ortho Nebraska

Classification- Position

- Kennedy “Position” Classification System for Knee Dislocation

Type	Radiograph	Features
Anterior		Most Frequent: 40% Mechanism: Hyperextension No medial or lateral damage Sometimes intact PCL Vascular damage common
Posterior		Frequent: 30% Mechanism: Direct posterior drawer Sometimes ACL intact Vascular Damage Common

Type	Radiograph	Features
Medial/Lateral		Rare Occurrence Most of the time posteromedial or posterolateral corner ACL + PCL damage Vascular damage if posterior Nerve damage in medial dislocations
Rotary	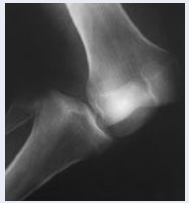	Rare occurrence Complex associated lesions

(Pardiwala et al., 2017; Medina, 2014)

Classification- Anatomic

- Schenck Anatomic Classification System for Knee Dislocations

Type	Description	Vascular Injury
KD I	Knee dislocation with either cruciate intact	0%
KD II	Bicruciate injury with collaterals intact	0%
KD III	Bicruciate injury with one collateral ligament injury	
	KDIIIM- Bicruciate injury with MCL injury	17% - 43%
	KDIIIL- Bicruciate injury with LCL injury	32% - 33%
KD IV	Bicruciate injury with both collateral ligament injury	10% - 60%
KD V	Periarticular fracture dislocation	0-6%

Ortho Nebraska

(Pardiwala et al, 2017; Moatshe et al., 2017; Peksun et al., 2010; Medina, 2014)

Importance of the Clinical Evaluation Process

- Must be purposefully evaluated
  - Deformity - 50% of knee dislocations spontaneously reduce prior to being seen by medical professional
  - History - Focusing on mechanism of injury, history of peripheral vascular disease
  - Physical Examination - Ligamentous testing to assess for ligament damage, likelihood of vascular injury

(Pardiwala et al., 2017)

Importance of the Clinical Evaluation Process

- Assessment for neurological deficits
  - Any deficiency in motor or sensory function should be noted
  - Peroneal nerve most injured
    - Seen in 20% - 41% of knee dislocations depending on mechanism of injury

- Monitor for compartment syndrome
  - Can be early or late sign
  - Sign of reperfusion injury

(Dervin et al., 2011)

Importance of the Clinical Evaluation Process

- Assessing for vascular injury
  - Possibly most important part of the initial assessment
    - Along with neurological status, could have disastrous complications if missed
  - Arterial injury found in 7-60% of knee dislocations
  - Look for “hard” signs of vascular injury
    - Any of these signs need immediate vascular surgery consultation:
      - Decreased or absent dorsal pedis and posterior tibial pulses
      - Increased capillary refill time
      - Expanding hematoma
      - Signs of ischemia

(Dervin et al., 2011)

Importance of the Clinical Evaluation Process

- Assessing for vascular injury

  At the venue

Method	Sensitivity	Specificity	Accuracy
Dorsal Pedis Pulse	98%	86%	88%
Posterior Tibial Pulse	92%	81%	83%

*Study demonstrated that 32% of patients with vascular injuries associated with knee dislocations sustained damage to the popliteal artery. Of those, 30% still had palpable pulses.

(Weinberg et al., 2016; Armstrong et al, 2003)

Importance of the Clinical Examination

Physical Exam Maneuvers

- Assessing for vascular injury

Method	Sensitivity	Specificity	Accuracy
Dopplerable Pulses	89%	89%	89%
ABI < 0.9	96%	99%	98%

(Weinberg et al., 2016; Beksac, 2016)

What is the ABI?

- The ankle-brachial index is a simple, reliable means for diagnosing vascular injury following knee dislocation
- Ratio of systolic distal artery with highest pressure over the higher systolic brachial pressure of the upper extremities
- ABI of less than .9 suggests increased likelihood for vascular injury

ABI Value	Interpretation
1.0 - 1.4	Normal
0.9 - 1.0	Acceptable
Less than 0.9	Possible Vascular Injury

(Measuring and Understanding, 2019)

ABI- What Does the Research Say?

- Study 1: 100% sensitivity, specificity and positive predictive value
- Study 2: Positive likelihood ratio- 95%
- Study 3: ABI and palpable dorsal pedis pulse
  - Sensitivity- 100%
  - Specificity- 98%
  - Positive Predictive Value- 93%
  - Negative Predictive Value- 100%
  - Accuracy- 98%

    *No patients with a diagnosis of vascular injuries within six months when they had a normal physical exam
- Study 4: 99% Specificity
  - Subjectivity of physical exam
  - Ankle brachial index more objective
  - Angiography justified if ABI is less than 0.9

Ortho Nebraska

(Mills et al., 2004; Gray, 2015; Stannard et al., 2004; Weinberg et al., 2016, Herickhoff & Safran, 2019)

When to Perform an ABI

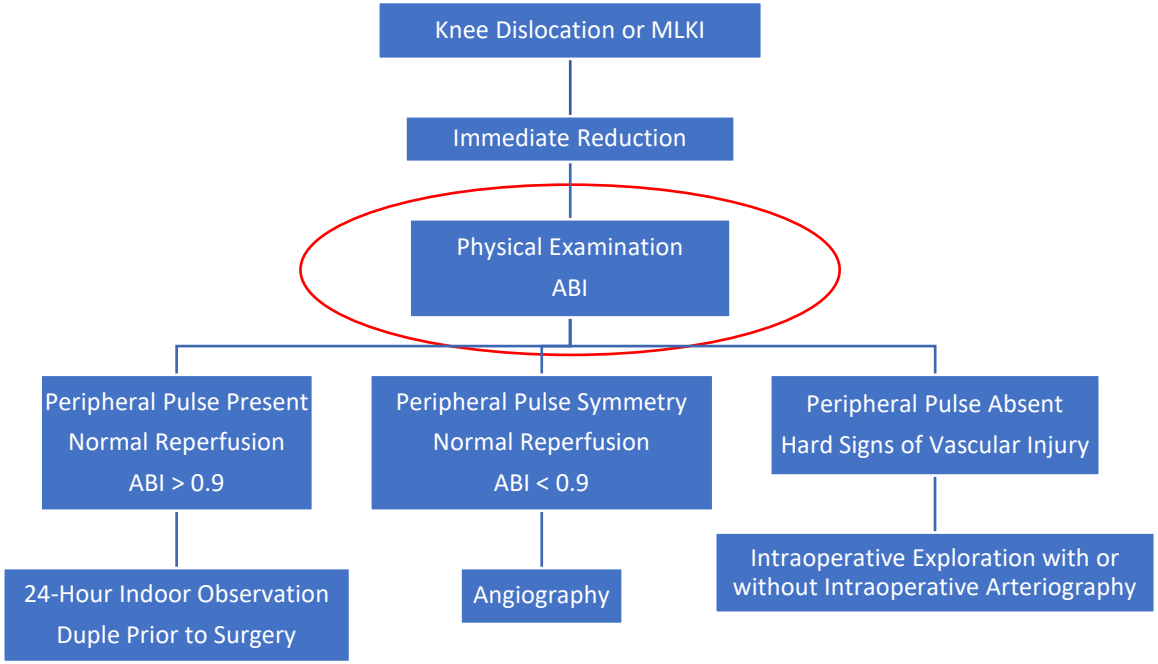

(Maslaris et al., 2018)

Ortho Nebraska

Tools Needed to Perform ABI

- 5 or 10 MHz Doppler Instrument or stethoscope
  - Ultrasound Gel if using Doppler
- Blood pressure cuff

  Regular or large for the arm

  Typically, regular cuff will work for the leg

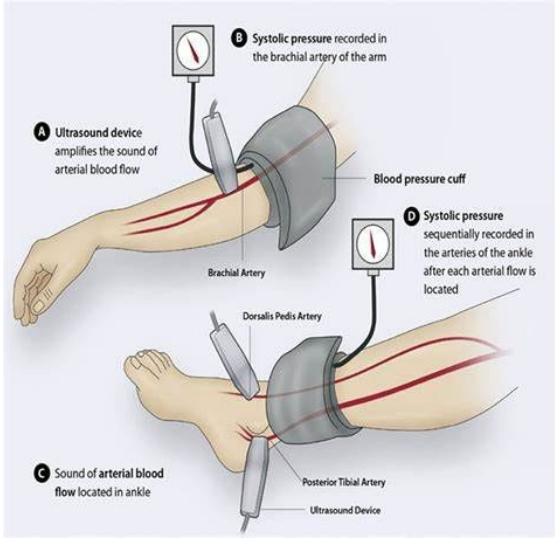

(Measuring and Understanding, 2019; Florida Vein Specialists, 2019)

Ortho Nebraska

Can ABI be Calculated with a Stethoscope?

Can we measure the ankle–brachial index using only a stethoscope? A pilot study

GAL Carmo[a], A Mandil[b], BR Nascimento[a], BD Arantes[a], JC Bittencourt[c], EB Falqueto[a] and AL Ribeiro[a]

- Study looking at measurement of ABI with Doppler versus stethoscope for patients with peripheral artery disease
- Similar correlations to using stethoscope ABI in trauma
  - Access to and skill in use of Doppler
  - Early diagnosis creates early opportunities for emergent treatment
- Researchers felt the stethoscope ABI was a useful method and correlated well with Doppler readings
- Mean stethoscope ABI 1.01 ± 0.15, and mean Doppler ABI 1.03 ± 0.20
- Sensitivity 71.4%, specificity 91%, negative predictive value 93.8%
- Healthcare providers need to recognize the strengths and weaknesses of using these methods

Ortho Nebraska

(Carmo et al., 2008; Takahashi, 2005)

Performing the ABI

- Patient should rest supine for 5-10 minutes before testing
- Blood pressure cuff is placed in proper position
  Arm- one inch above the antecubital fold
  Leg- Just above the malleoli
- Doppler probe or stethoscope placement
  Arm- Brachial artery
  Leg- Dorsalis pedis artery, posterior tibial artery
- Blood pressure cuff inflated up to 20 mmHg above flow signal disappearance, then deflate slowly until signal reappearance
- Sequence: Right arm, right leg, left leg, left arm

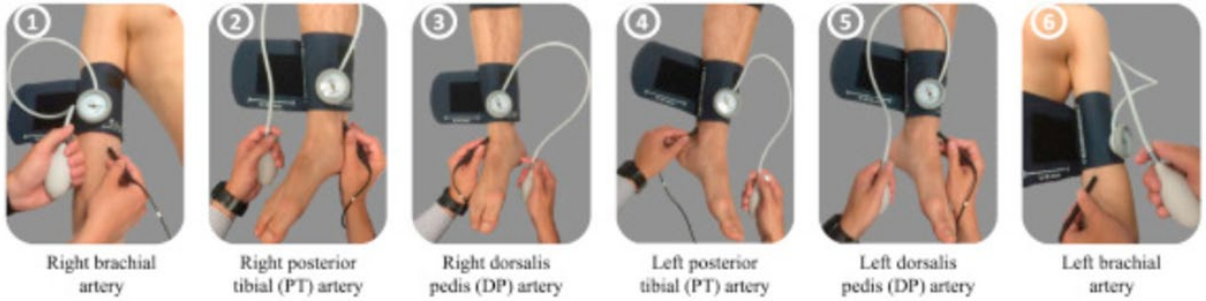

(Chaudru et al., 2016)

How to Calculate ABI

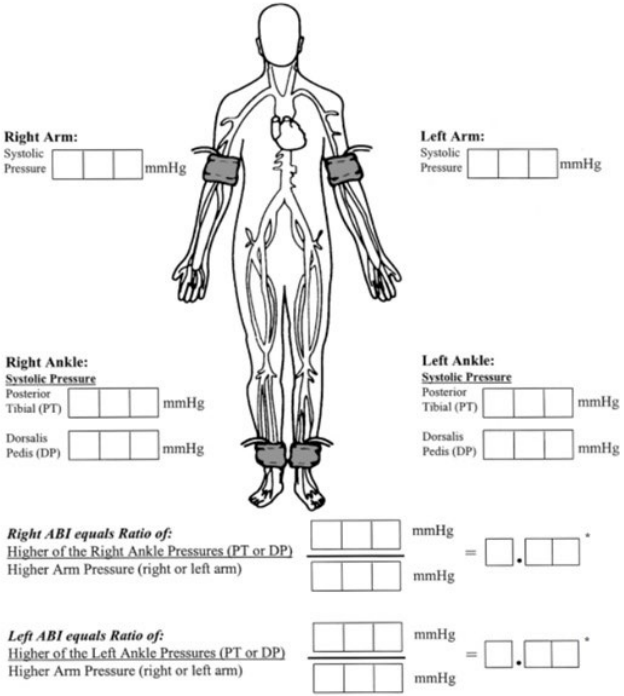

Right ABI equals Ratio of:
Higher of the Right Ankle Pressures (PT or DP) mmHg
Higher Arm Pressure (right or left arm) mmHg = .

Left ABI equals Ratio of:
Higher of the Left Ankle Pressures (PT or DP) mmHg
Higher Arm Pressure (right or left arm) mmHg = .

(ABI Worksheet, n.d.)

Next Steps

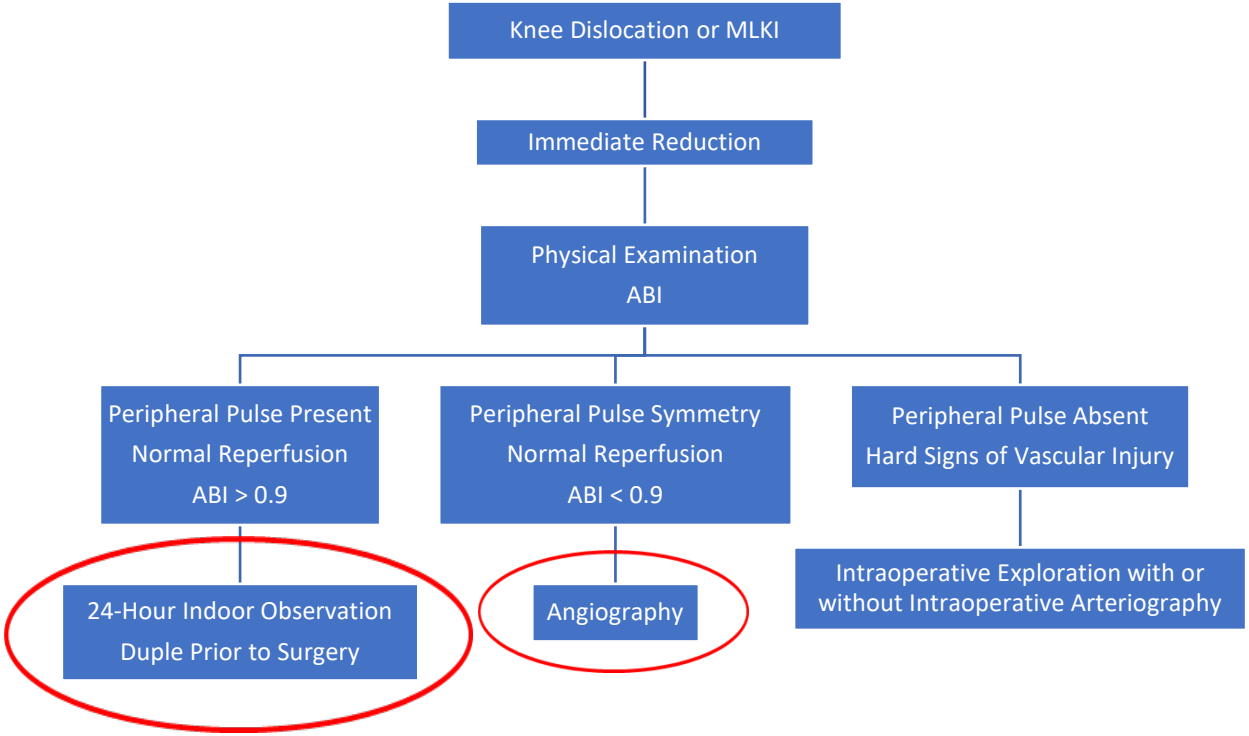

(Maslaris et al., 2018)

Ortho Nebraska

Immediate Takeaways

- Vascular injuries are most seen with anterior and posterior knee dislocations
- Hard signs of neurovascular injury = Immediate transport
- Higher likelihood in bicruciate ligament injuries with one or both collateral ligaments involved
- Dorsalis pedis, and posterior tibialis pulses not sufficient to rule out vascular injury
  - Satisfied with testing that is 89% accurate, and amputation rate 12%?

Clinical Bottom Line

- With a sensitivity of 96%, specificity of 99%, and accuracy of 98%, the ABI is an effective test that can be used to assess for a vascular injury.
- ABI's should be used in physical exam with assessment of dorsalis pedis and posterior tibialis pulses.
- A stethoscope can be used in place a of a doppler when performing an ABI. Accuracy is dependent on the comfortability and experience of the health care professional performing the exam.
- If ABI is less than 0.9- Advanced imaging including angiography.

Considerations

- What do clinicians say about using the ABI to assess for vascular injury
  - The 12% amputation rate seen are high trauma or missed
- Should be performed in an emergency room or lab setting
  - Hospital protocols may move straight to advanced imaging
  - Hospital politics- Levels of trauma center and who makes the call
- Could perform in athletic training facility in rural areas where decisions regarding where/how to transport is of concern
  - Trauma doctor making the call on possible vascular injury on your sideline?
  - Comfortability
  - Practicality
- Know the “magic words” when communicating with EMS an ER personnel

References

ABI worksheet. (n.d.). Retrieved from https://www.sononet.us/abiscore/documents/abi_sheets.pdf

Ankle brachial index (2012). Retrieved from https://www.youtube.com/watch?v=KnJDrmfIXGw

Armstrong, P.J., & Franklin, D.P. (2003). Treatment of vascular injuries in the multiple-ligament injured knee. *Operative Techniques in Sports Medicine, 11*(3), 199-207.

Beksac, B. (2016). CORR insights: Can vascular injury be appropriately assessed with physical examination after knee Dislocation? *Clinical Orthopaedics and Related Research, 474*, 1459-1460.

Carmo, G.A., Mandil, A., Nascimento, B.R., Arantes, B.D., Bittencourt, J.C., Falqueto, E.B., & Ribeiro, A.L. (2008). Can we measure the Ankle-brachial index using only a stethoscope? A pilot study. *Family Practice, 26*(1), 22-26.

Chaudru, S., de Mullenheim, P.Y., Le Faucheur, A., Kaladji, A., Jaquinandi, V., & Mahe, G. (2016). Training to perform ankle-brachial Index: Systematic review and perspectives to improve teaching and learning. *European Journal of Endovascular Surgery, 51*(2), 240-247.

Dervin, G., Liew, A., Simon, D., Cohen, S., & Johnson, D. (2011). Knee dislocation: The Ottawa Approach. *Intraoperative Techniques in Sports Medicine, 19*(1), 12-26.

Florida vein specialists explain the ankle-brachial index test, and how it is used to detect vascular disease. (2019). Retrieved from Http://www.southpalmcardiovascular.com/florida-vein-specialists-explain-the-ankle-brachial-index-test-and-how-it-is-used-to-Detect-vascular-disease/

Ortho Nebraska

References

Gray, J.L. (2011). Management of arterial and venous injuries in the dislocated knee. Operative Techniques in Sports Medicine, 23(4), 362-371.

Herickhoff, P., & Safran, M. (2019) Knee dislocation in athletes. Complex Knee Ligament Injuries, 181-194.

Maslaris, A., Brinkmann, O., Bungartz, M., Krettek, C., Jagodzinski, M., & Liodakis, E. (2018). Management of knee dislocation prior to ligament Reconstruction: What is the current evidence? Update of a universal treatment algorithm. European Journal of Orthopaedic Surgery & Traumatology, 28(6), 1001-1015.

Measuring and understanding the ankle brachial index (ABI). (2019). Retrieved from https://www.apastyle.org/learn/faqs/web-page-no-Author.html

Medina, O., Arom, G.A., Yeranosian, M.G., Petrigliano, F.A., & McAllister, D.R. (2014). Vascular and nerve injury after knee dislocation: a systematic Review. Clinical Orthopaedics and Related Research, 472(9), 2621-2629.

Mills, W.J., Barei, D.P., McNair, P. (2004). The value of the ankle-brachial index for diagnosing arterial injury after knee dislocation: A prospective study, Journal of Trauma, 56(6), 1261-1265.

Moatshe, G., Chahla, J., LaPrade, R.F., Engebretsen, L. (2017). Diagnosis and treatment of multiligament knee injury: State of the art. Journal of ISAKOS: Joint Disorders & Orthopaedic Sports Medicine, 2(3), 152-161.

Oeskun, C.J., Levy, B.A., Fanellie, G.C., Stannard, J.P., Stuart, M.J., MacDonald, P.B., Marx, R.G., Boyd, J.L., & Whelan, D.B. (2010). Diagnosis and Management of knee dislocations. The Physician and Sportsmedicine. 4(38), 101-111.

Pardiwala, D.N., Rao, N.N., Anand, K., & Raut, A. (2017). Knee dislocations in sports injuries. Indian Journal of Orthopedics, 51(5), 552-562.

Ortho Nebraska

References

Peroneal nerve. (2019). Retrieved from https://www.mayoclinic.org/diseases-conditions/foot-drop/multimedia/peroneal-nerve/img -20008172

Sheth, U. (2016). MCL knee injuries. Retrieved from https://www.orthobullets.com/knee-and-sports/3010/mcl-knee-injuries

Stannard, J.P., Sheils, T.M., Lopez-Ben, R.R., McGwin, G. Robinson, J.T., & Volgas, D.A. (2004). Vascular injuries in knee Dislocations: The role of physical examination in determining the need for arteriography. *The Journal of Bone and Joint Surgery, 56*(6), 1261-1265.

The structures of the posterolateral corner. (n.d.), Retrieved from https://www.kneeguru.co.uk/KNEEnotes/courses/posterolateral-corner-injuries-knee/structures-posterolateral-corner

Takahashi, O., Shimbo, T., Rahman, M., Musa, R., Kurokawa, W., Yoshinaka, T., & Fukui, T. (2006). Validation of the auscultory method For diagnosing peripheral arterial disease. *Family Practice, 23*(1), 10-14.

Weinberg, D.S., Scarcella, N.R., Napora, J.K., & Vallier, H.A. (2016). Can vascular injury be appropriately assessed with Physical examination after knee dislocation? *Clinical Orthopaedics and Related Research, 474*(6), 1453-1458.

Wilson, C. (2019). Knee Pain explained. Retrieved from https://www.knee-pain-explained.com/knee-joint-anatomy.html

Ortho Nebraska