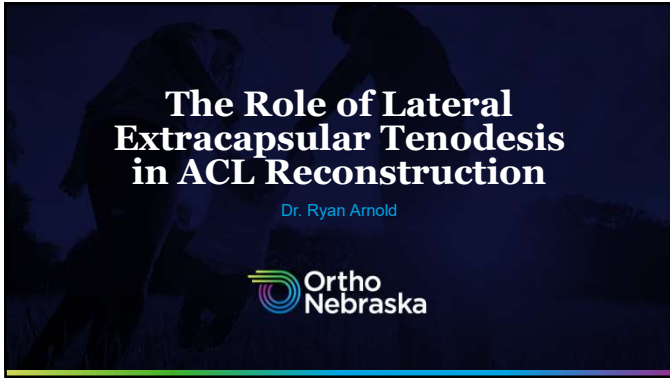
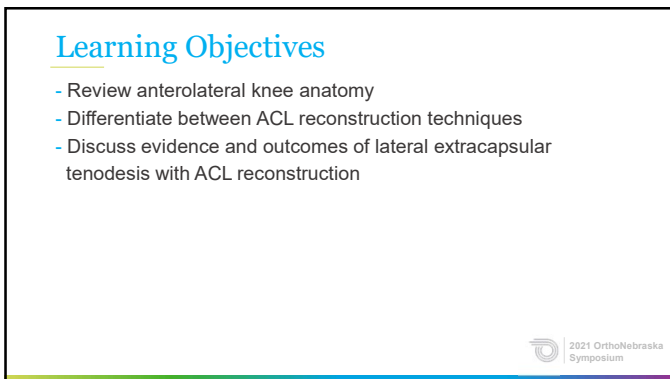




1



2



3

ACL Injuries of the Knee

- ACL Tears are a common injury in the athletic population.
 - Annual Incidence of 70 injuries per 100,000 population.
 - Roughly 225,000 injuries per year in the United States.
 - (4000 members of the AOSSM)
- Wiggins et. Al (2016) noted that nearly 1 in 4 young athletic patients who sustain an ACL injury will go on to sustain another ACL injury at some point in their athletic career if they return to high-risk sports.
 - Reducing reinjury risk has focused on improved mechanics and complete rehabilitation, graft selection, biology of healing and surgical techniques/anatomic reconstruction.

2021 OrthoNebraska Symposium

4

ACL Injuries of the Knee

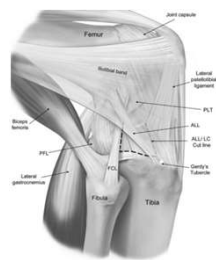
- For many patients, an isolated ACL reconstruction will lead to an excellent functional outcome.
- Ristanis, et. Al (2005) and others have demonstrated that there is a group of patients who will have residual excessive rotational instability placing them at higher risk of rupture.
- Ongoing attempts (Musahl, et. Al, 2012) have focused on identifying this patient population and improving their outcome.

2021 OrthoNebraska Symposium

5

Anterolateral Complex of the Knee

- The anterolateral soft tissues of the knee have received increased attention because of the "rediscovery" of the Anterolateral Ligament (ALL).

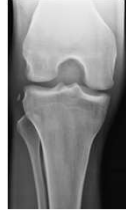
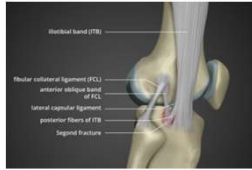
2021 OrthoNebraska Symposium

6

Anterolateral Complex of the Knee

- Segond originally described an association between injury to the anterolateral structures of the knee in conjunction with ACL disruption in 1879.



2021 OrthoNebraska Symposium

7

Anterolateral Complex of the Knee

- Hughston et. Al (1976) postulated that disruption of the middle third of the lateral capsular ligament led to Anterolateral Rotatory Instability (ALRI) of the knee and was accentuated by ACL disruption.
- Galway et. Al (1980) described the lateral pivot shift as a sign and symptom of ACL insufficiency and recognized the anterolateral structures as secondary stabilizers of the ACL.

2021 OrthoNebraska Symposium

8

Anterolateral Rotatory Instability (ALRI)


- Defined as excessive forward rotation of tibial plateau w/ excessive lateral opening of the joint.
 - There is excessive internal rotation of tibia on femur in flexion.
 - As knee extends, subluxation is reduced by the bony stability, and a jerk is noted which is basis for the pivot shift test.

2021 OrthoNebraska Symposium

9

Anterolateral Complex of the Knee


- Noyes, et. Al (2017) showed that the IT Band acts as a secondary restraint to tibial translation and internal rotation.
 - The IT Band and ALL functioned in some knees as the primary restraint to internal rotation at high flexion angles.
 - An injured Anterolateral Complex (ALC) puts significant force on the ACL in sports involving cutting, jumping and pivoting.



10

Anterolateral Complex of the Knee

- Terry, et. Al (1993) showed that in a clinical trial of 82 consecutive knees, concurrent ALC injury occurred in 93% of patients with an ACL Tear.
- Combined injury to the ACL and ALC has been reported to demonstrate greater rotatory instability and pivot shift relative to isolated ACL injuries.



11

Anterolateral Complex of the Knee


- The Anterolateral Complex is defined by the part of the ITB between the Kaplan fibers proximally and its tibial insertion, which forms a functional unit.
- Consists of:
 - The Superficial and Deep IT Band.
 - The capsulo-osseous layer of the IT Band and the anterolateral capsule.



12

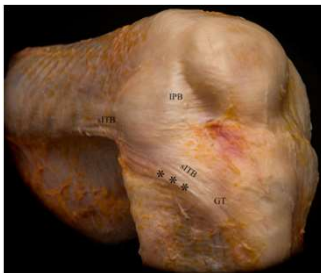
Anterolateral Complex of the Knee

- Numerous Studies have promoted the existence of a discrete ligament on the anterolateral aspect of the knee which has been termed the Anterolateral Ligament (ALL).
- Published descriptions of the femoral insertion, obliquity of the ligament position and other parameters have varied widely.




13

Anterolateral Complex of the Knee

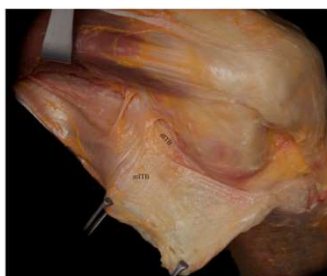

Layer 1 including the superficial iliotibial band (sITB) and iliopatellar band (IPB). Asterisks indicate the folding of the posterior part of the sITB at higher degrees of knee flexion. GT Gerdy tubercle.




14

Anterolateral Complex of the Knee

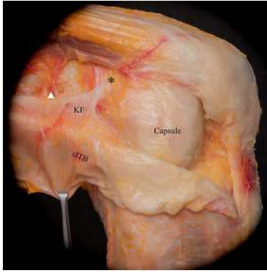


Posterior reflection and distal release of the superficial iliotibial band (ITB) revealed the obliquely aligned fibers of the middle layer of the ITB (mlITB). As seen here, these fibers best be seen in the supracondylar region. dlITB, deep layer of the ITB.



15

Anterolateral Complex of the Knee

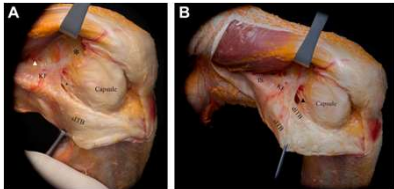


Reflection of the superficial iliotibial band (sITB) revealed its firm attachment to the distal femoral metaphysis via the Kaplan fibers (KF). The KF are in close proximity to the branches of the superior genicular artery (white arrowhead) and have accessory insertions (asterisk) proximal and anterior to the femoral epicondyle. Further, the superficial layer of the anterolateral capsule becomes visible.

2021 OrthoNebraska Symposium

16

Anterolateral Complex of the Knee

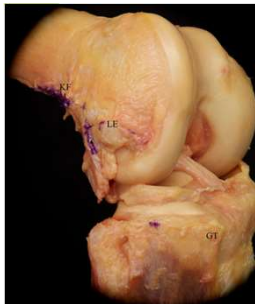

(A) With further posterior reflection of the superficial iliotibial band (sITB) and blunt separation from the deeper layers, the capsulo-osseous layer (black arrowhead) can be appreciated. The white arrowhead indicates the branches of the superior genicular artery. (B) Proximal, the longitudinally aligned fibers of the intermuscular septum (IS) can be differentiated from the Kaplan fibers (KF). Further, retraction of the sITB reveals the deep ITB (dITB), which merges with the sITB distally. No distinct anterolateral ligament is distinctly observed. The asterisk highlights the accessory insertion of the KF.

2021 OrthoNebraska Symposium

17

Anterolateral Complex of the Knee

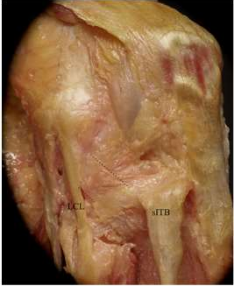


Removal of the anterolateral soft tissues showed the insertions and origins of the different layers of the iliotibial band (purple ink). The tibial insertion of the capsulo-osseous layer on the lateral tibial tuberosity (dotted circle) is located about halfway between the Gerdy tubercle (GT) and the fibular head. On the femoral side, the capsulo-osseous layer is continuous with the fascia of the lateral gastrocnemius tendon (white arrowhead). KF, Kaplan fiber insertion; LE, lateral epicondyle (after removal of the lateral collateral ligament).

2021 OrthoNebraska Symposium

18

Anterolateral Complex of the Knee

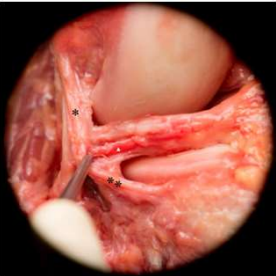


Reflection of the superficial iliotibial band (sITB) and its deep layers reveals the anterolateral joint capsule with a thickening (mid-third capsular ligament; area between the 2 dotted lines) anterior to the lateral collateral ligament (LCL). This mid-third capsular ligament is observed 35% of the time.

2021 OrthoNebraska Symposium

19

Anterolateral Complex of the Knee



Removal of the anterolateral capsule revealed the coronary ligament, consisting of the menisofemoral (*) and meniscotibial (***) ligaments. Medial to the coronary ligament, the inferior genicular artery (white arrowhead) runs from posterior to anterior.

2021 OrthoNebraska Symposium

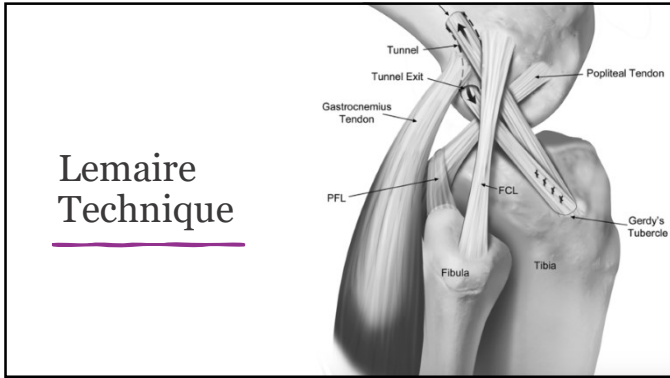
20

Historical Significance of ALCR

- Early extra-articular procedures were performed as isolated operations for ALRI.
- Proposed to eliminate rotatory instability and anterior tibial translation.
- Fell out of favor due to poor long-term outcomes including graft failure, residual instability, and joint over constraint.
- Non-anatomic nature may have contributed to poor outcomes.

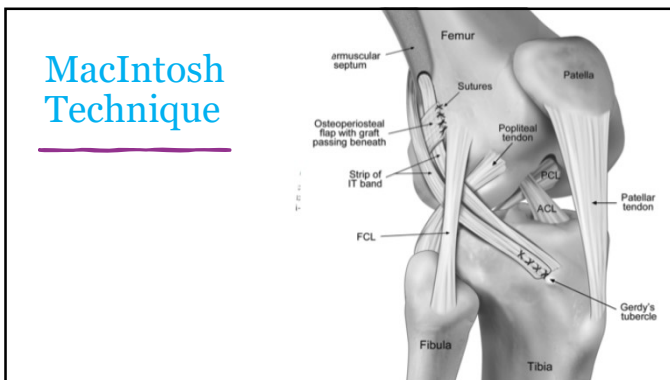
2021 OrthoNebraska Symposium

21



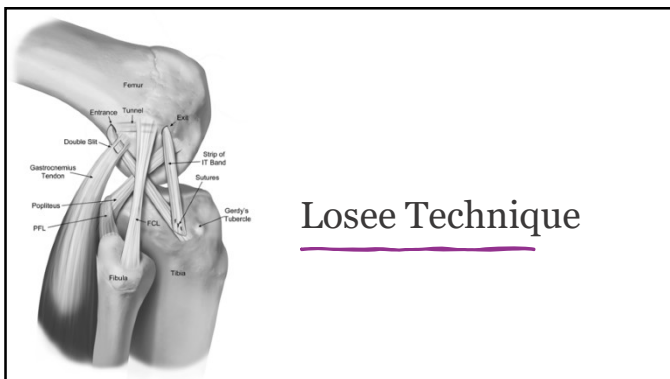
Lemaire Technique

22



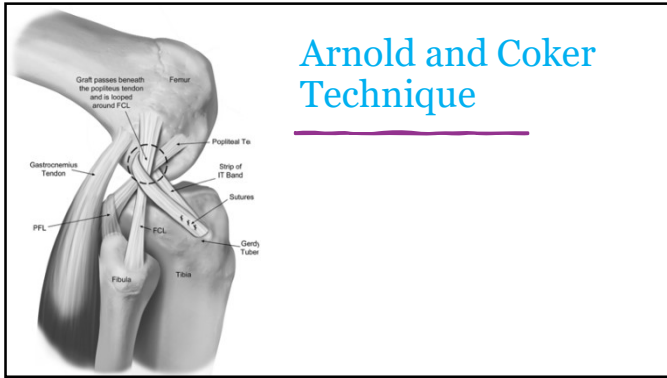
MacIntosh Technique

23



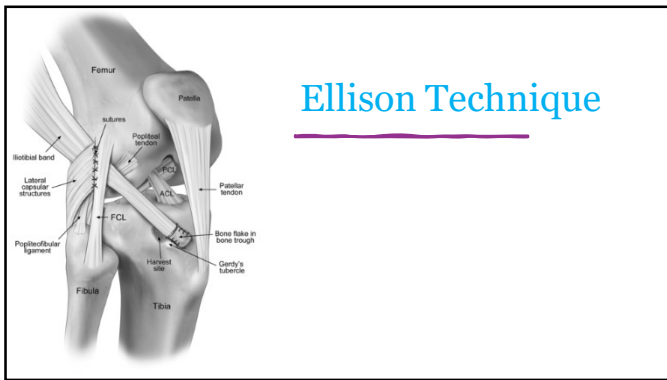
Losee Technique

24



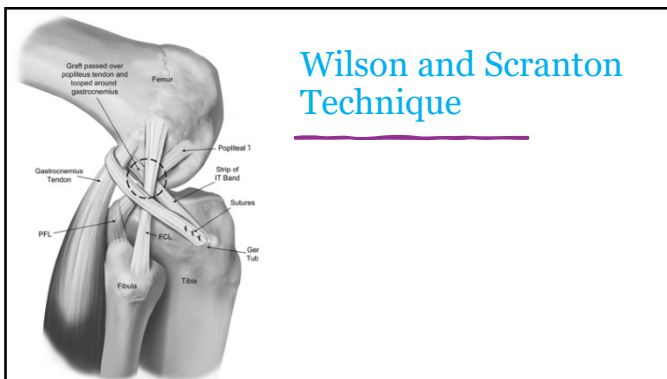
Arnold and Coker Technique

25



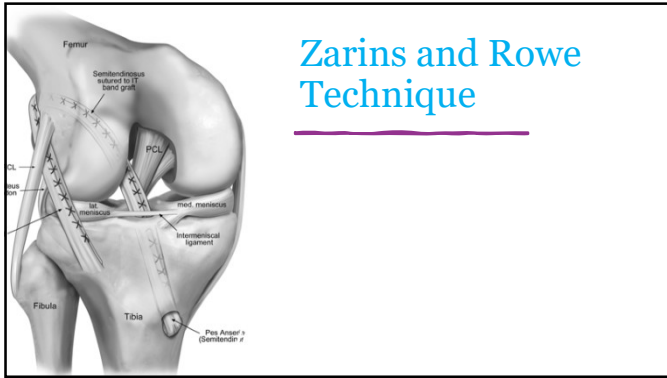
Ellison Technique

26



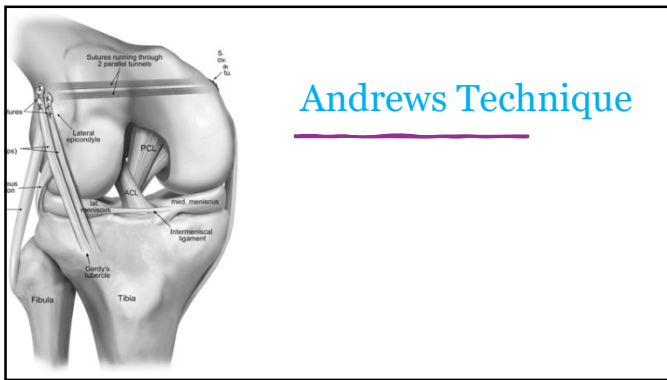Wilson and Scranton Technique

27



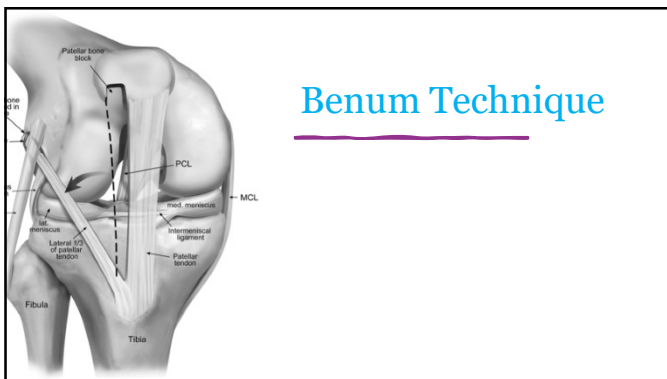
Zarins and Rowe Technique

28



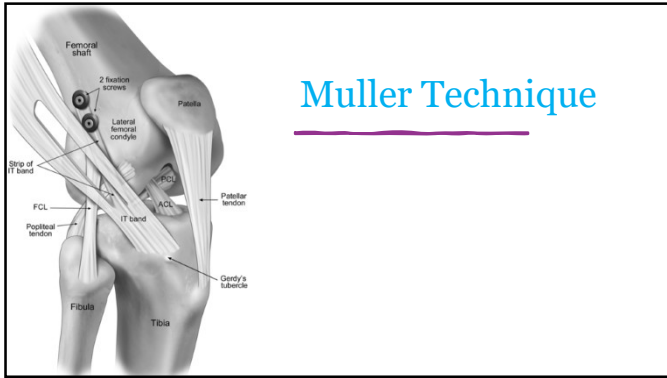
Andrews Technique

29

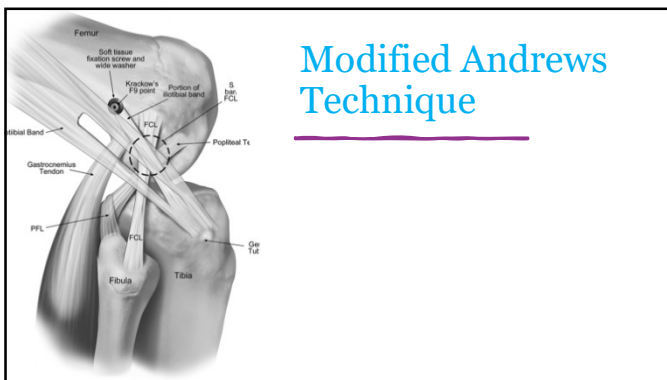


Benum Technique

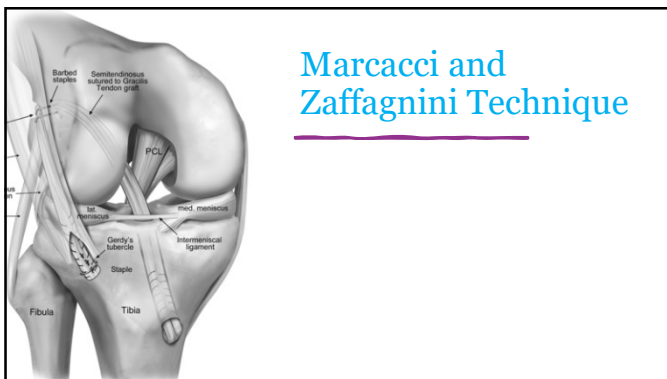
30



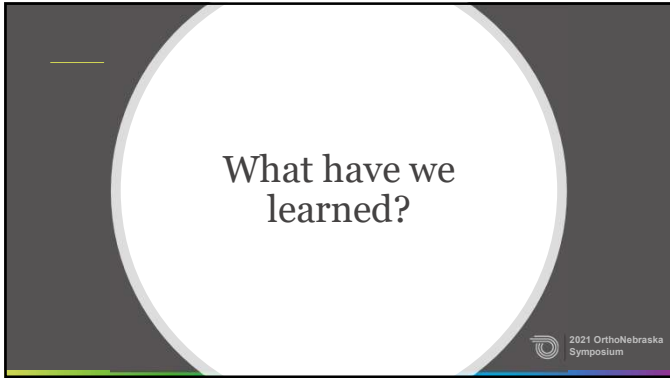
31



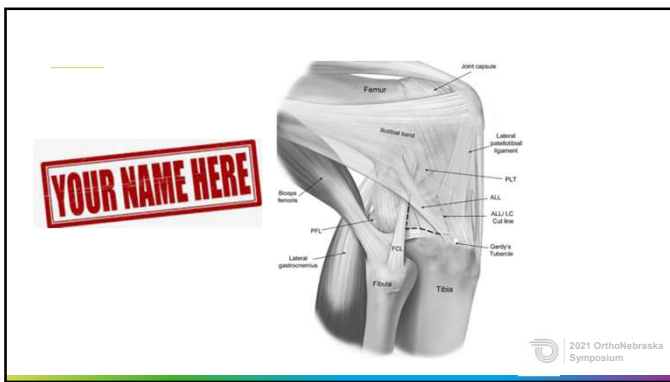
32



33



34



35

Isolated LET Outcomes


- Neyret et. Al (1994) – Lemaire Technique. 16/31 Satisfied amateur skiers. 12/15 positive pivot shift at 4.5 years.
- Ireland et. Al (1980) – MacIntosh Technique. 74% RTS. 16% Positive Pivot Shift at 2 yrs.
- Amirault et. Al (1988) – MacIntosh Technique. 52% Good Outcome at 11 years.

2021 OrthoNebraska Symposium

36

Isolated LET Outcomes


- Ellison et. Al (1979) - Ellison Technique. 16% Failure requiring reoperation. 83% good to excellent at 4years.
- Kennedy et. Al (1978) – Ellison Technique. 57% good to excellent at 1 yr. 85% positive pivot shift.
- Reid et. Al (1992) – Ellison Technique. 75% positive pivot shift. 91% positive Lachman at 11 years.



37

Biomechanics Meta-Analysis (Slette, et. al 2016)

- Isolated LET reduced (overconstrained) internal rotation of the tibia across flexion angles 0-90 °.
 - Risk of OA? Graft Elongation?
- Isolated LET reduced anterior tibial translation but did not normalize.
- LET combined with intraarticular reconstruction reduced tibial translation and forces on the graft.



38

Biomechanics Meta-Analysis (Slette, et. al 2016)


- Verified previous conclusions that ACL and ALC collectively inhibit ALRI in the intact knee.
- Despite various surgical techniques, most studies exhibited similar biomechanical results.
- Non-anatomic reconstruction did not restore native kinematics.



39

Biomechanics Meta-Analysis (Slette, et. 1 2016)

- While Isometry was difficult to achieve and may not exist for the ALC, Kittl et. Al (2015) reported that inserted proximal to the lateral epicondyle, coursed deep to FCL was nearly isometric between 0-90°.
- Addition of LET to ACLR may be practical when the ACL graft will require additional protection.
 - Obese, Highly active (sport dependent), severe ALC compromise.



40

ACL + LET Outcomes Data

- Dejour (1988) – Augmented BTB ACL with Lemaire. 83% good to excellent at 3 yrs.
- Obrien et. Al (1991) - BTB ACL with MacIntosh. No improvement in stability. Routine use, no patient selection.
- Anderson et. Al (2001) – Randomized BTB, HS and HS + Losee. No additional benefit to the Losee.



41

ACL + LET Outcomes Data


- Devitt, et. Al (2017)
 - Odds of Postop Pivot Shift were 52% lower in patients who underwent ACL/LET compared to ACL alone.
 - Difference was most significant in those that underwent ACL reconstruction greater than 12 months post injury and correlated to a more significant pivot shift preoperatively.
 - Insufficient evidence to determine affect on postop ROM, Lachman exam, Quad or HS strength, IKDC score, and return to sport.
 - Strong evidence that LET decreases translation of lateral compartment of the femur on stress radiographs.



42

ACL + LET Outcomes Data


- Follow-up Study: Devitt, et. Al (2017)
 - No increase in long-term rates of OA with ACL/LET reconstructions.
- Zaffagini et. Al (2017) – Combined ACL + Marcacci. Good or excellent 86%. 2% Rupture Rate. 12% Pivot Shift. 19yrs.
- Vadala et. Al (2013) – 60 Females. ACL with HS vs. HS + Arnold/Coker. Randomized. 57.1% Pivot shift in HS. 18.6% Pivot in combined. 4yrs.



43

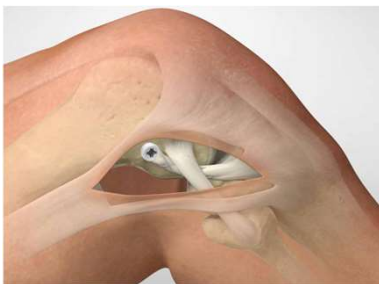
Ongoing studies

- University of Western Ontario (STAbiLiTY trial).
 - Randomized controlled 600 pts. 14-25yo. Competitive Pivoting Sports. Grade II pivot or generalized ligamentous laxity.
 - HS Auto vs. HS Auto and Modified Lemaire.
 - No statistically significant differences between groups in Hop Testing or Limb Symmetry Index at 6, 12, or 24 months.
 - Self-reported function, Pain scores, Quad Peak force favored the ACLR alone group at 3 (P = .01) and 6 months (P = .02) postoperative but was similar by 12 months postoperative.



44


Modified Lemaire Technique



45

Current Considerations/Indications


- International ALC Consensus Group:
 - Revision ACLR.
 - High-grade rotational laxity (a grade 2 or 3 pivot shift).
 - Generalized ligamentous laxity or genu recurvatum of 10°.
 - A young patient (25 years old) returning to a contact pivoting sport.
- Contraindications:
 - Posterolateral Corner Injury
 - Lateral Compartment Osteoarthritis
 - *** Lateral Meniscus Deficiency



46

Conclusions

- Combined injury to the ACL and ALC exhibits greater ALRI compared to isolated ACL injuries.
- Lateral extra-articular procedures in isolation are insufficient at restoring normal anterior stability, overconstrain the knee and restrict internal rotation.
- In high-risk patients, combined ACLR and LET may provide improved rotational control and reduced risk of recurrent injury.



47

Sources

Rostarski S, Storgli N, Patras K, et al. Excessive tibial rotation during high-demand activities is not restored by anterior cruciate ligament reconstruction. *Arthroscopy*. 2005;21:1323-1329.

Masani V, Sui R, Zaffagnini S, et al. The role of static and dynamic rotatory laxity testing in evaluating ACL injury. *Knee Surg Sports Traumatol Arthrosc*. 2012;20:800-812.

Arnault J, Carroon J, MacIntosh D, et al. Chronic anterior cruciate ligament deficiency. Long-term results of MacIntosh's lateral patellar stabilization reconstruction. *Bone & Joint Journal*. 1988;70:622-624.

Ellen A. Distal tibial-band transfer for anterolateral rotatory instability of the knee. *J Bone Joint Surg Am*. 1978;61:330-337.

Neylet P, Paterno R, Donald S, et al. Extra-articular tenodesis for anterior cruciate ligament rupture in amateur skiers. *Br J Sports Med*. 1994;28:31-34.

Ineland J, Trickey R, Walker DM. Anterolateral rotatory instability of the knee joint. An early analysis of the Elson procedure. *J Bone Joint Surg Am*. 1978;60:1031-1039.

Kennedy J, Stewart R, Walker DM. Anterolateral rotatory instability of the knee joint. An early analysis of the Elson procedure. *J Bone Joint Surg Am*. 1978;60:1031-1039.

Ried J, Henke G, Katenak A, et al. The Elson tibial-band transfer for a torn anterior cruciate ligament of the knee. Long-term follow-up. *J Bone Joint Surg Am*. 1992;74:1392-1402.

Dejour R, Walch G, Neyret P, et al. Results of surgically treated chronic anterior laxities. Apropos of 251 cases reviewed with a minimum follow-up of 3 years. *Rev Chir Orthop Reparatrice Appar Mot*. 1988;74:622-636.

O'Brien S, Warren R, Pawlo H, et al. The tibial band lateral sling procedure and its effect on the results of anterior cruciate ligament reconstruction. *Am J Sports Med*. 1991;19:21-25.

Anderson AF, Snyder RB, Lipscomb AB Jr. Anterior cruciate ligament reconstruction: a prospective randomized study of three surgical methods. *Am J Sports Med*. 2001;29:272-279.

Zaffagnini S, Maccioni G, Gerosa A, et al. Over-the-top ACL reconstruction plus extra-articular lateral tenodesis with hamstring tendon grafts: prospective evaluation with 20-year minimum follow-up. *Am J Sports Med*. 2017;45:3233-3242.


Vakkila A, Iorio R, De Carl A, et al. An extra-articular procedure improves the clinical outcome in anterior cruciate ligament reconstruction with hamstrings in female athletes. *Int Orthop*. 2013;37:187-192.

Billy L, Lording T. Clinical results of lateral extra-articular tenodesis. *Techniques in Orthopaedics*. 2018;33:232-238.

Selke E, Mikula J, Sifton J, et al. Biomechanical results of lateral extra-articular tenodesis procedures of the knee: A systematic review. *Arthroscopy*. 2016;32:2652-2611.

Quill B, Ball S, Ardern C, et al. The role of lateral extra-articular tenodesis in primary anterior cruciate ligament reconstruction. *The Orthopedic Journal of Sports Medicine*. 2017; 5(10): 1-11.

Harbitz E, Aabera M, Burnham J, et al. The anterolateral complex of the knee. *The Orthopedic Journal of Sports Medicine*. 2017; 5(10): 1-11.



48

